

Novel Antifungal Agents for Pityriasis Versicolor: A Comparative Study on Ivermectin and *Calvatia Craniiformis*

Ammar K. Al-Khateeb, Omar S. Al-Hamdani, and Kareem A. Al-Rubaye

Department of Medical Microbiology, College of Medicine, University of Basrah, Iraq; Department of Dermatology, College of Medicine, University of Al-Mustansiriya, Baghdad, Iraq

ABSTRACT

Objectives: isolation of *Malassezia furfur* from pityriasis versicolor (PV) patients; *in vitro* evaluation of ivermectin and *Calvatia craniiformis* antifungal activity as novel agents for treatment; finally evaluation of age, gender, contact with animals and marital status as risk factors for *M. furfur* infections. **Methods:** Sixty PV patients were included. *M. furfur* isolated on Sabouraud dextrose agar. ivermectin aqueous solutions (0.5%), (1%) and (2%); *C. craniiformis* alcoholic extracts (50mg, 100mg, 200mg, 400mg, 600mg, 800mg and 1 gm) were used to determine their novel antifungal activity against *M. furfur* *in vitro* using broth dilution susceptibility test. **Results:** The majority of patients (61.7%) in age group (27-32) years followed by (21-26) years. Males : females represent (83.33%: 16.67%). Significant difference was reported among patients in age, gender, marital status and anatomic location of body area infected with *M. furfur*. Age has no significant correlation with other proposed risk factors of *M. furfur* infection. Gender significantly correlated with contact with dogs and birds as well as marital status (p value =0.000). Marital status significantly correlated with contact with animals(dogs and birds, p value =0.000);infected area of the body (p value =0.000).Contact with dogs and birds significantly correlated with anatomic location of infected area of the body (p value =0.000). A total of (75%) of patients respond to treatment with (2 %)ivermectin aqueous solution, the meantime for clearance was 23.5 days. A total of (90 %) of patients respond to treatment with alcoholic extract of *C. craniiformis* (1000 mg), meantime for clearance was 24days. Significant difference in time of complete curing reported between groups (p<0.05). Significant difference was detected between the following *C. craniiformis* concentrations: 100mg and 200 mg; 200 mg and 400 mg; 400 mg and 600 mg; 100mg and 1000 mg; 800 mg and 1000 mg; 400 mg and 1000 mg. Significant difference between 1% and 2% as well as 0.5% and 2% Ivermectin was determined. **Conclusions:** *M. furfur* considered an important etiology for PV. Alcoholic extract of *C. craniiformis* (1000 mg), and (2%) ivermectin aqueous solution, significantly inhibit the *in vitro* growth of *M. furfur*. The effect was proportionally associated with concentration. The meantime of clearance for clinical lesions, using these agents was shorter than fluconazole and hence can be used as a novel topical antifungal agent for treatment of PV associated *M. furfur* infections. The main risk factor for PV associated *M. furfur* infection was direct contact with dogs and birds while infection indirectly affected by gender .The main affected sites were neck and shoulder together, neck and trunk respectively.

Keywords: *Malassezia furfur*, Ivermectin , *C. craniiformis*, Pityriasis versicolor.

INTRODUCTION

on the trunk⁵. It *Malassezia*, a lipophilic yeasts are commensal skin organisms of warm-blooded vertebrates¹. They are opportunistic pathogens that may cause systemic and skin disorders in human and animals^{1,2}. They considered as medically important yeasts because of their involvement in the etiology of some important skin disorders including pityriasis versicolor, folliculitis, seborrheic dermatitis and dandruff³, psoriasis, confluent reticulate papillomatosis and seborrheic blepharitis. *Malassezia* spp. have been shown to cause more deep-seated infections, including mastitis, sinusitis, septic arthritis, malignant otitis externa, fungaemia, pulmonary vasculitis, peritonitis and meningitis^{4,5}. The lesions of pityriasis versicolor (PV) due to *Author for Correspondence: alizziibrahim@gmail.com starts to grow on the skin surface results in changing of skin colour, which appear as lightly reddish brown on white skin. This is most often seen on the neck, upper chest, upper arms and back .The infection produced no symptoms but some patients get itching especially with sweating⁶.

malassezia spp. , seen most commonly

Alteration in the pigmentation of the skin either hypo or hyper-pigmentation, considered as one of the characteristic of PV, and often the factor for seeking diagnosis and treatment⁵. The diagnosis confirmed by microscopic examination of skin scraping with 10% KOH. Lesions examined microscopically show the transition of the organism from the yeast to the hyphal phase, producing a characteristic 'spaghetti and meatballs' appearance⁵. Samples can be cultured on Sabouraud glucose agar and modified Dixon agar, incubated at 31 °C for 7 days for conformation³.

M. furfur treated symptomatically with either topical or systemic medications such as 2.5% selenium disulfide or ketoconazole containing shampoos. Widespread infections are treated with short courses of itraconazole at 200mg/ day for seven days or fluconazole⁶. Ivermectin (22,23 -dihydroavermectin B_{1a} + 22,23-dihydroavermectin B_{1b}) is a broad-spectrum anti-parasitic medicine . It is a chemical derivatives of soil microorganisms belonging to the *Streptomyces avermitilis* fungus⁷. Ivermectin is a member of

macrocyclic lactones, named *ivermectins*, which proved active against a variety of nematode and arthropod parasites. The drug causes paralysis in susceptible parasites⁷; it interrupts the gamma-aminobutyric acid-induced neurotransmission of many parasites (including mites)^{8,9}.

Antimicrobials of plant origin are in great demand due to their widespread biological activities providing a source for the discovery of many types of effective bioactive compounds. Of these, very few successful drugs are now available for the treatment of fungal infections, especially for superficial mycoses¹⁰. Ever since the importance of the distribution of pharmacologically active principles in higher plants was understood and acknowledged, the importance of such plant-derived medicines in modern therapeutic practice has paved the way for the development of new drug leads that are safe, cost-effective, and ecofriendly¹¹. *Calvatia craniiformis* (*C. craniiformis*) is puffball mushroom belongs to Basidiomycota division, Lycoperdaceae family, *Calvatia* genus¹². *C. craniiformis* has many usage in traditions of different area around the world¹², *Calvatia species* have found widespread use in the folk medicines of various cultures, especially as a haemostatic (styptic) and wound dressing, as well as for a variety of other ailments such as leucorrhoea, pneumaturia, inflammation, diarrhoea in calves¹². Current study designed to isolate *M. furfur* for the first time in Iraq from patients with dermatological manifestations of PV in Diyala province-Iraq. In addition, to evaluate antifungal activity of *ivermectin* and *C. craniiformis* (*in vitro*) and the possible use as novel treatment for PV. Finally, to evaluate age, gender, contact with animals and marital status as a risk factors for *M. furfur* infections.

MATERIAL AND METHODS

The patients

This cross-sectional, hospital based study was conducted in dermatology department-, Baqubah teaching hospital – Diyala province, during period from June 2014 to June 2015. Sixty patients with clinical presentation of PV were examined (50 male and 10 females), age range from (15-50) years. All patients were from rural areas. Full history was taken from each patient concerning other cutaneous complaints, history of evolution and progression of PV, the duration of the disease, treatment modalities and ensured that every patient had stopped any treatment at least one month before starting the current therapy. The participants asked about age, marital status, employment and contact with animals.

This study conducted according to the principles of Helsinki declaration. A full explanation of the purpose of this study in all patients before starting. Dully filled consent form obtained from all patients who agree to participate in the study. Approval of an ethical review committee of pathology department, college of veterinary medicine, Diyala University, Iraq, No.(05/2014) taken before initiation into the work.

Sampling and identification of *M. furfur*

Patients with PV diagnosed based on clinical criteria and confirmed by demonstration of organisms by examination of skin scrapings. Skin scales scraped off with a sterile blade and transferred to the laboratory. They were mounted in KOH (10%) for direct microscopic examination, to look for the presence of short angular hyphae and clusters of spores 'spaghetti and meatball' appearance³. Demonstration of round to ovoid yeast cells and short filaments in scales from patients is considered the most diagnostic finding in direct microscopy of *M. furfur* infections³.

The specimens were inoculated on Sabouraud dextrose agar (SDA), containing 0.05% chloramphenicol (Merck, Darmstadt, Germany) and 0.05% cycloheximide (Sigma, St Louis, MO, USA) and overlay with olive oil¹³. All plates incubated at 30°C for ten days and monitored daily. Microscopic examination of positive culture stained with cotton lactophenol blue stain revealed yeast budding of *M. furfur*.

To assess the physiological properties of the yeasts, catalase reaction was determined by using a drop of hydrogen peroxide (30%) onto a culture smear on a glass slide. The production of gas bubbles, indicative of release of oxygen, was considered a positive reaction¹⁴. Another confirmatory tests, tween assimilation test and splitting of esculin for identification of *M. furfur* were done in the central public health laboratory¹⁵.

Preparation of antifungal agents

Ivermectin aqueous solution was prepared in 0.5 %, 1 % and 2% for local application¹⁶. Fruiting body of *C. craniiformis* mushroom was dried and crushed in sterile petri dish to obtain a yellow – brown powder. Then 100 gm from the powder dissolved in 100 ml ethanol 70% and mixed perfectly. The concentration become (1000 mg / 1 ml) and considered as stock solution¹⁷. Suspensions of *C. craniiformis* mushroom (50 mg, 100mg, 200mg, 400mg, 600mg, 800mg and 1000 mg) were prepared by dissolving of the powder with ethanol 70%.

Strategy of clinical antifungal usage

For evaluation of antifungal agents, patients were divided in to 3 groups, group A, include 20 patients treated by 2% *ivermectin* solution twice daily for two months. Group B, include 20 patients treated by 1000mg of *C. craniiformis* suspension twice daily for two months. Group C (control group) include 20 patients, treated by *fluconazole* 150mg capsule once weekly for two months. In all groups, The mycological cure was defined as the obtaining of negative KOH smear and negative wood's lamp examination for treated individual¹⁸.

Assessment of antifungal activity in vitro A fully recognized with complete growth *M. furfur* colonies were exposed to aqueous *ivermectin* solution (0.5 %, 1 % and 2%) and alcoholic extracts of *C. craniiformis* (50mg, 100mg, 200mg, 400mg, 600mg, 800mg and 1000 mg). After 5 days of incubation at 37°C, the plates were observed for the growth at various concentrations of *C. craniiformis*, *ivermectin* and *fluconazole*. The diameter of inhibition zones was measured from the point where the growth significantly decreased and was recorded to

the nearest millimeter. The lowest concentration of extract and /or drug that inhibits the growth of *M. furfur* in broth dilution susceptibility test was determined as minimal inhibitory concentration.

Statistical Analysis

Data shown as the mean \pm SD .Statistical analysis performed using SPSS version 16 software. The following tests were used, one-way analysis of Variance (ANOVA),T-test used to find out the significance of differences between two groups that composed from continuous variables. Pearson chi-square test used for noncategorical data and Spearman's correlation used for ranked data, the level of Significance was ($P<0.05$).

RESULTS

M. furfur colonies appear as white to tan creamy-colored colony with smooth pasty consistency on sabouraud's media. The cells appeared bottling shaped when observed microscopically as shown in (Figure 1&2). Patient's demography and proposed risk factors reported in table (1). The mean age of patients was (27.65 years).The majority of patients (61.7%) at age group (27-32) years . The least age group was (45-50) years. Significant difference in infection rate was reported among age groups. Males : females represent (83.33% /16.67%(with significant difference in infection rate. All patients were unemployed. Contact with birds reported in (60%) and (40%) with dogs, with significant difference in infection rate. Infections of neck and shoulder reported in (60%), neck alone (35%) and trunk alone (5%) with significant difference in infection rate. Married patients represent(65%) with significant difference, in infection rate, compared with unmarried, as shown in table (1).

Age considered as independent risk factor and has no significant correlation with any other proposed risk factors of *M. furfur* infection (table 2). As the majority of infections reported among males, gender was correlated with bird and dogs contact as well as marital status of infected individuals (p value =0.000). Marital status of infected individuals correlated with contact with animals and anatomical location of infected area of the body (p value =0.000).Animals contact correlated with anatomical location of infected area of the body (p value =0.000). Table (3) showed that in group A,15/20 (75%) of patients respond to treatment with *ivermectin* aqueous solution (2 %), meantime for clearance was 23.5 days. In group B, 90 % (18/20) of patients respond to treatment with alcoholic extract of *C. craniiformis* (1000 mg),meantime for clearance was 24days. In control group, 14/20 (70%) patients respond to *fluconazole* (150mg). Meantime for clearance was 41days. Significant difference in time of complete curing reported between groups($p<0.05$). The patients in groups (A and B) show minimal side effect such as slight irritation as in figures (4a,b), (5a,b) and (6a,b) which represent untreated and treated patients respectively.

Table (4), reveals antifungal activity of *C. craniiformis*; aqueous solution of *ivermectin* compared with *fluconazole*. No significant difference between 50mg and 100 mg of *C. craniiformis* concentrations. Significant difference

between 100mg and 200 mg; 200 mg and 400 mg; 400 mg and 600 mg; 100mg and 1000 mg; 800 mg and 1000 mg; 400 mg and 1000 mg of *C. craniiformis* concentrations. No significant difference between 600mg and 800 mg of *C. craniiformis* concentrations as shown in figure (3) .

No significant difference determined between 0.5% and 1% *ivermectin* aqueous solution . However, significant difference between 1% and 2% ; 0.5% and 2% was determined as shown in figure (2).

DISCUSSION

Pityriasis versicolor is a common scaling dermatosis usually confined to small patches of skin, particularly on the trunk and shoulders. Lesions are very superficial areas of hypopigmentation or hyperpigmentation that are chronic and asymptomatic. The rash is most notable in the summer as tanning occurs in surrounding skin while sparing infected areas of skin¹⁹. Many reasons suggested for the disturbance in pigmentation on the skin, including a block in the transfer of melanosomes to keratinocytes and inhibition of melanin production either by *azelaic acid* or by *lipoxygenase*²⁰. Tryptophan metabolites of *M. furfur* have been shown to induce apoptosis in *melanocytes*, with concomitant decreases in melanin synthesis that may account for depigmentation associated with one form of PV^{5,21}.

Table 1: Patients demography and proposed risk factors.

Parameters			P value
Age(years)	Minimum	15	0.000
	Maximum	50	
	Mean± SD	27.65± 7.89	
	15-20	5(8.4%)	
	21-26	13(21.7%)	
	27-32	37(61.7%)	
	33-38	0(0%)	
	39-44	3(5%)	
	45-50	2(3.4%)	
Gender	Male	50(83.33%)	0.000
	Female	10(16.67%)	
Marital status	Married	39(65%)	0.020
	Unmarried	21(35%)	
Employment	Employed	0(0%)	ND
	Unemployed	60(100%)	
Contact with Animals	Dogs	24(40%)	0.121
	Birds	36(60%)	
Body area infected with <i>M.furfur</i>	Neck	21(35%)	0.000
	Neck and shoulder	36(60%)	
	Trunk	3(5%)	

ND: not detected

Table 2: Correlations of proposed risk factors with *M.furfur* infection.

Spearman's rho		Gender	Marital status	Contact with Animals	Infected area of Body
Age	rho	-0.091	0.146	-0.029	0.117
	P value	0.491	0.267	0.826	0.375
Gender	rho		-0.609**	0.548**	0.235
	P value		0.000	0.000	0.071
Marital Status	rho			-0.899**	-0.385**
	P value			0.000	.002
Contact with Animals	rho P value				0.428** 0.001

*Correlation is significant at the 0.05 level (2-tailed)

**Correlation is significant at the 0.01 level (2-tailed).

Table 3: Response to treatment with novel antifungal agents and the time of complete curing.

No. of Patients per group	Antifungal Agent	NO.(%) of patients respond to treatment	Mean time for complete curing . (Days)
---------------------------	------------------	---	--

M. furfur is one of the most prevalent *species* involved in the etiology of different *malassezia* infections, especially PV. Its high morphological variation in direct microscopy requires a rapid identification of this *species* among *malassezia* isolates³. The mean age of PV patients in the current study close to that reported by^{14,20}, found that population densities peaking between 20-45 years. However, there is a great variation in the presence and density in various skin locations. In the current study, neck and shoulders were the major sites while the trunk was the least one. The distribution of *malassezia species* on head and trunk region is parallel with the density and activity of pilosebaceous glands in these areas. The difference in density and *species* of fungus in different body areas is attributed to lipid content and different lipid components in each body area²². In adults, the frequency and density of colonization are related to the age and to the activity of the sebaceous glands in the area studied. The highest population densities were noted from chest, upper back and forehead, and men yielded more yeasts in lower back and thigh than women¹⁴. The density of *malassezia spe* Significant difference *($P < 0.05$)

cies on the skin decreased with increasing age, which was probably due to a reduction in the level of lipid on the skin¹⁴. Current finding confirms the isolation of *M. furfur* from PV cases in Iraq for the first time. The casual relationship between PV and *M. furfur* reported by other countries²²⁻²⁴. In most PV cases, *malassezia*, as a part of normal skin flora, are not pathogenic, unless they assume a mycelial form⁵. This may be triggered by various factors, including high temperature, hyperhidrosis, familial susceptibility, and immunosuppression²⁵. In current study, a correlation between the prevalence of *M. furfur* and gender of the subjects has been observed, and this comes in line with¹⁵. However, statistical difference was noted among age groups although no correlation between age and infection was detected, which come in line with others²⁵. Other studies determine no such difference²⁰.

In this study, significant difference between married and unmarried subjects concerning *M. furfur* infection with inverse correlation between marital status, anatomical location of infected area of the body mainly neck, and shoulder and contact with dogs and birds. This finding reflect the fact that married subjects especially male, in local population become more exposed to *M. furfur* infec

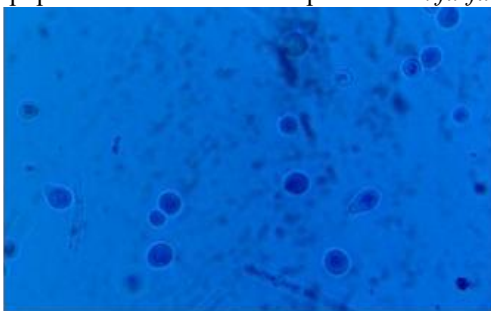


Figure 1: Show budding of *M. furfur* stained with cotton lactophenol blue stain.



Figure 2: Effects of different concentrations of ivermectin aqueous solution on growth of *M. furfur* compared with fluconazole 150 mg (sabouraud Dextrose agar).



Figure 3: Effects of different concentrations of alcohol extract of *C. craniiformis* on growth of *M. furfur* (sabouraud Dextrose agar).

tion from animal sources as a result of direct handling of domestic dogs and birds which include the race pigeons. The main affected area in this study include neck and shoulder, less frequently the trunk and this may attributed to several factors includes but not limited to, humidity and high temperature, hyperhidrosis, familial susceptibility, and immunosuppression²⁵. A range of skin microenvironmental factors, such as the bacterial microbiota present, pH, salts, immune responses, cutaneous biochemistry, and physiology, may play a role in adherence and growth of *malassezia species*, favouring distinct genotypes depending on the geographical area and/or the skin sites²⁶, which come in conflicts with others, reported that the trunk represent the main affected sites²⁰. The medications used in this study when compared with other studies using other remedies, are cheap, available, easily intake and safe. The medications previously used in treatment of PV include azole compounds²⁷. The present study disclosed that alcoholic extract of *C. craniiformis* (1000 mg) was effective in 90% of PV cases, which respond to treatment and the meantime for clearance was 24days. Aqueous solution of ivermectin (2 %) was effective in (75%) of PV with meantime for clearance was 23.5 days. In control group, (70%) patients respond to treatment with fluconazole (150mg), and the meantime for clearance was 41days.

The mode of action for *ivermectin* as a parasitocidal agent by binding selectively and with high affinity to glutamate chloride ion channels, commonly found in invertebrate nerve and muscle cells. It stimulates the release of the inhibitory neurotransmitter gamma-aminobutyric acid (GABA) from presynaptic nerve terminals and encourages its binding to the postsynaptic receptors. The resultant increase in chloride ions leads to hyperpolarization of cells, and eventually paralysis and death of the parasites²⁸. Topically applied *ivermectin* is absorbed by fungal cell and is actively transported across cell membranes by P-glycoprotein (P-gp). P-glycoprotein 1 (P-gp) also known as multidrug resistance protein 1 (MDR1) or ATP-binding cassette sub-family B member 1 (ABCB1) is an important protein of the cell membrane that pumps many foreign substances out of cells. It is an ATP-dependent efflux pump for xenobiotic compounds with broad substrate specificity²⁹. It is responsible for decreased drug accumulation in multidrug-resistant cells. Substrate enters P-gp either from an opening within the inner leaflet of the membrane or from an opening at the cytoplasmic side of the protein³⁰. *Ivermectin* has been known to be a member of the impressive list of inhibitors of P-gp-mediated transport. *Ivermectin* are able to interfere with P-gp transport activity. Because macrocyclic lactones are slowly transported by P-gp, it is suggested that when *ivermectin* binds to P-gp, the binding sites become unavailable to other compounds³⁰. *Ivermectin* also exerts significant anti-inflammatory effects by inhibition of lipopolysaccharide-induced production of inflammatory cytokines such as TNF and IL1 through inhibition of nuclear factor-kappa B pathway³¹. *Ivermectin* play a role as immunomodulator by stimulates production of the anti-inflammatory cytokine IL-10³². IL-10 is a cytokine with multiple, pleiotropic, effects in immunoregulation and inflammation. It downregulates the expression of Th1 cytokines, MHC class II antigens, and costimulatory molecules on macrophages. It also enhances B cell survival, proliferation, and antibody production. IL-10 can block NF-kB activity, and is involved in the regulation of the JAK-STAT signaling pathway. By all these events *ivermectin* enhance the clinical relive from infection²⁵.

The possible cause of complete curing in (75%) and failure in 25% of patients treated with aqueous solution of *ivermectin* (2 %) because *ivermectin* is highly unstable in the presence of water and it is difficult to have stable

Table 4: antifungal activity of *c. Craniiformis* versus aqueous solution

Antifungal agents	Concentrations of Alcohol extract of <i>C. craniiformis</i>			
<i>C craniiformis</i>	50 mg	100 mg	200 mg	400 mg
	Diameter of <i>M.furfur</i> colony (Mean ± SE) in (mm)			
	29± 1.3	23.5± 0.3	20 ± 1.3	16.75
	(a)	(*b)	(*c)	(*d)
	(a): No significant difference between concentrations			
	(*b): Significant difference between concentrations			
	(*c): Significant difference between concentrations			
	(*d): Significant difference between concentrations			
	(e): No significant difference between concentrations			
	(*f): Significant difference between concentrations			
	(*h) : Significant difference between concentrations			
	(**h): Significant difference between concentrations			
	Concentrations of aqueous solution of <i>Ivermectin</i>			
<i>ivermectin</i>	0.5%		1%	
	Diameter of <i>M.furfur</i> colony (Mean ± SE) in (mm)			
	15.5 ± 0.3		12.5 ± 0.3	
	(a)		(*b)	
	(a) No significant difference between concentrations			
	(*b) Significant was between concentration 1%			
	(*c) Significant difference between concentrations			
<i>fluconazole</i>	Concentration of <i>Fluconazole</i> 150 mg			
	Diameter of <i>M.furfur</i> colony (Mean ± SE) in (mm)			
	± 1.3			

pharmaceutical compositions, including *ivermectin*. It exhibits the difficulty of being very sparingly soluble and rarely stable in water as a pharmaceutical solvent, and it is sensitive to an aqueous environment. However, *ivermectin* has very poor solubility in water, at a level of about 0.005 mg per ml at room temperature³³. This sensitivity to water can result in chemical instability of the active principle and/or in crystallization of the initially dissolved active principle. This sensitivity to water thus limits its formulation in dermatological compositions administered via the topical route. The phenomena of chemical decomposition and/or of crystallization of *ivermectin* in the presence of water have as consequences a reduction in or loss of effectiveness and uncertainty with regard to the dose of active principle employed during the administration thereof, which militates against the desired objective^{33,34}. Other factors may have a role in failure of treatment using aqueous solution of *ivermectin* (2 %) is the requirement for more time for clinical cure and increase the concentration of *ivermectin* for effective results.

Anti *M furfur* activity of *C. craniiformis* not reported previously. In the current study, 90 % of patients respond to treatment with alcoholic extract of *C. craniiformis* (1000 mg). Meantime for clearance was 24days compared with *fluconazole* 150 mg. *In vitro*, anti *M furfur* activity of *C. craniiformis* appears to be concentration dependent. Anti *M furfur* activity of *C. craniiformis* is more potent using (1000 mg) compared with other concentrations. The medical analysis of *C. craniiformis* proved the presence of three components; the first is *calvatic acid*, which has chemical formation P-carboxyphenylazoxycarbonitrile³⁵. This calvatic acid proves a strong action against the yeast

and fungi like *Saccharomyces cerevisiae* and several in (73%), four weeks after the last treatment. Oral *candida species* and *Trichophyton asteroides*¹⁷. The second components from chemical analysis and spectroscopic means of the mushroom powder is hydroxyphenylazoforamid derivatives which has three chemical compounds, 4-hydroxyphenyl-1-azoforamid, 4-hydroxyphenyl-ONN-azoforamid and 2-methylsulfonyl 4-hydroxy-6-methylthiophenyl-1-azoforamid, it is known craniformin (phenolic tautomer of rubroflavin), and also three components are known steroids, ergosta4,6,8 (14), 22-tetraene-3-one, ergosta-7,22-diene-3-OH and ergosterol peroxide³⁶. The hydroxy phenyl azoforamid derivatives or craniformin have phenolics in its formation which are endowed with interesting biological activities as a broad spectrum bactericidal and fungicidal effect represented by *Candida albicans* and *Aspergillus niger*³⁷. The craniformin has azole compound which inhibits the synthesis of ergosterol by blocking the action of 14- α -demethylase and stop proliferation of the fungus³⁸. The action of azole compounds reveals inhibition fungal mRNA transcription³⁹. The chemical analysis of *C. craniiformis* powder which is done in white fields company for chemical and engineering studies and consultations in Baghdad – Iraq proved the presence of different materials as gallic acid and others. Gallic acid is a trihydroxybenzoic acid, a type of phenolic acid and found both free and as a part of tannins. Gallic acid seems to have anti-fungal properties⁴⁰.

The oral *fluconazole* used in this study is a triazole antifungal agent acts by inhibiting cytochrome P450-dependent ergosterol synthesis in fungal cells in a similar manner of *itraconazole* and *ketoconazole*²⁵. The efficacy of oral *fluconazole* reported in the present study comes closely to⁴¹, in which, the mycological cure using 150 mg *fluconazole* was reported

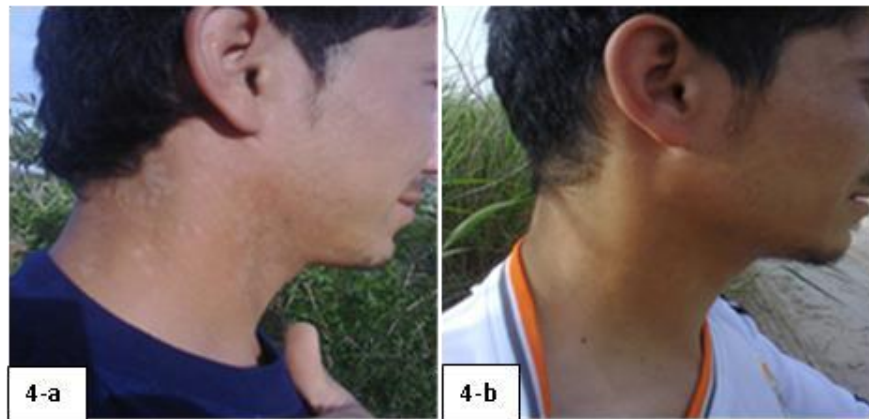

Figure (4): a:-lesions of *M. furfur* in untreated patient appear as white patches in cervico-fascial region . b:- clearance of the lesion after treatment with *C. craniiformis* suspension locally.

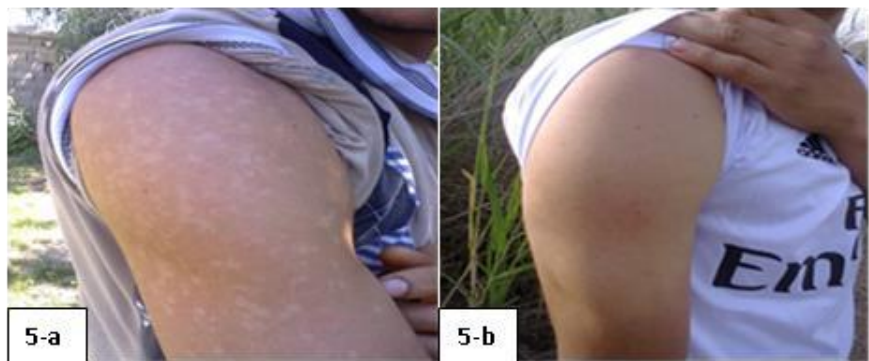

Figure (5): a:- *M. furfur* lesions in untreated patient appear as white patches in arm b: clearance of the lesion after treatment with *C. craniiformis* suspension locally.

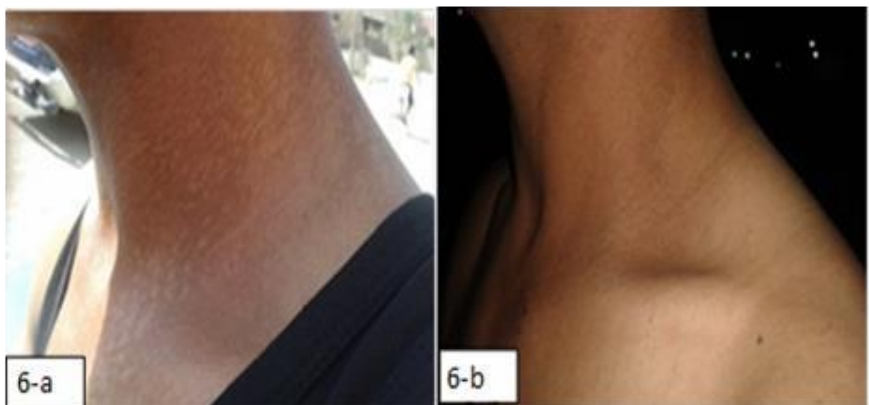

Figure (6) - a:- *M. furfur* lesion in untreated patient appear as white patches in neck and above sternum region . b: clearance of the lesion after treatment with ivermectin locally.

fluconazole therapy was found to be superior than other topical remedies like *clotrimazole* in the treatment of PV in terms of efficacy and patient compliance and also cost-effective for the patients⁴², but the efficacy depends on increasing of dose up to 300 mg weekly to be more potent, which is the main drawback due to possible toxicological effects^{25,42}.

CONCLUSIONS

M. furfur considered an important etiology for PV. Alcoholic extract of *C. craniiformis* (1000 mg), and (2%) ivermectin aqueous solution, significantly inhibit *in vitro* growth of *M. furfur*. The effect was proportionally associated with concentration. The meantime of clearance for clinical lesions, using these agents was shorter than fluconazole and hence used as a novel topical antifungal agent for treatment of PV associated *M. furfur* infections. The main risk factor for PV associated *M. furfur* infection was direct contact with dogs and birds, while infection indirectly affected by gender. The main affected sites were neck and shoulder together, neck, followed by trunk respectively.

RECOMMENDATIONS

This study recommends further investigations for antifungal activity of *C. craniiformis* fractions and stable aqueous formulation of ivermectin for PV topical treatment that will be safer and effective therapy.

REFERENCES

- Prohic A, Jovic Sadikovic T, Krupalija-Fazlic M, Kuskunovic-Vlahovljak S: Malassezia species in healthy skin and in dermatological conditions. International journal of dermatology 2015.
- Cafarchia C, Gallo S, Romito D, Capelli G, Otranto D: New insights into the Diagnosis and the Pathogenicity of Malassezia Yeasts. Veterinary research communications 2006, 30:231- 34.
- Ghahfarokhi MS, Abyaneh MR: Rapid identification of Malassezia furfur from other Malassezia species: A major causative agent of pityriasis versicolor. Iranian Journal of Medical Sciences 2015, 29:36- 9.
- Welsh O, Gonzalez GM: Dermatophytosis (Tinea) and other superficial fungal infections. In Diagnosis and Treatment of Fungal Infections. Edited by: Springer; 2015:245-60.
- Ashbee HR: Recent developments in the immunology and biology of Malassezia species. FEMS Immunology & Medical Microbiology 2006, 47:14- 23.
- Habif TP: Clinical Dermatology, a color guide to Diagnosis and therapy edn 6th china: Elsevier Health Sciences; 2015.
- Cavero R, Akerreta S, Calvo M: Medicinal plants used for dermatological affections in Navarra and their pharmacological validation. Journal of ethnopharmacology 2013, 149:533- 42.
- Hay R: Malassezia, dandruff and seborrhoeic dermatitis: an overview. British Journal of Dermatology 2011, 165:2-8.
- Jurenka J: Therapeutic applications of pomegranate (Punica granatum L.): a review. Alternative medicine review 2008, 13:128.
- Afolayan AJ, Grierson DS, Mbeng WO: Ethnobotanical survey of medicinal plants used in the management of skin disorders among the Xhosa communities of the Amathole District, Eastern Cape, South Africa. Journal of ethnopharmacology 2014, 153:220-23
- Lalitha SG, Ramachandrappa LT, Krishnamurthy S, Basavaraju J, Thirumale S: Insignificant antifungal activity of plant extracts on Malassezia furfur. Journal of Pharmaceutical Negative Results 2016, 7:16.
- Coetze J, van Wyk AE: The genus Calvatia ('Gasteromycetes', Lycoperdaceae): A review of its ethnomycology and biotechnological potential. African Journal of Biotechnology 2009, 8:6007- 15.
- Naga Padma P, Anuradha K, Divya K: Comparison of potency of antifungal action of dandruff shampoos and different plant extracts. International Journal of Medical Research & Health Sciences 2015, 4:327- 31.
- Prohic A, Simic D, Sadikovic TJ, Krupalija-Fazlic M: Distribution of Malassezia species on healthy human skin in Bosnia and Herzegovina: correlation with body part, age and gender. Iranian journal of microbiology 2014, 6:253.
- Khosravi A, Eidi S, Katirae F, Ziglari T, Bayat M, Nissiani M: Identification of different Malassezia species isolated from patients with Malassezia infections. World J Zoology 2009, 4:85- 9.
- Lo P-KA, Williams JB: Solubilization of ivermectin in water. Edited by: Google Patents; 1983.
- Umezawa H, Takeuchi T, Iinuma H, Tanabe O: Production of a new antibiotic, calvatic acid. Edited by: Google Patents; 1976.
- Mohite A, Gugle A, Kote R, Jadhav V: A Comparative Study of Efficacy, Safety and Relapse Rate of Three Drugs; Systemic Ketoconazole, Systemic Itraconazole and Topical Oxiconazole in the Treatment of Pityriasis Versicolor. MVP Journal of Medical Science 2015, 2:76-80.
- Gaitanis G, Magiatis P, Hantschke M, Bassukas ID, Velegraki A: The Malassezia genus in skin and systemic diseases. Clinical microbiology reviews 2012, 25:106- 41.
- Ramadan S, Sortino M, Bulacio L, Marozzi ML, López C, Ramos L: Prevalence of Malassezia species in patients with pityriasis versicolor in Rosario, Argentina. Revista Iberoamericana de Micología 2012, 29:14-9.
- Krämer HJ, Podobinska M, Bartsch A, Battmann A, Thoma W, Bernd A, Kummer W, Irlinger B, Steglich W, Mayser P: Malassezin, a novel agonist of the aryl hydrocarbon receptor from the yeast Malassezia furfur, induces apoptosis in primary human melanocytes. Chembiochem 2005, 6:860- 65.
- Lee Y, Yim S, Lim S, Choe Y, Ahn K: Quantitative investigation on the distribution of Malassezia species on healthy human skin in Korea. Mycoses 2006, 49:405- 10.
- Salah SB, Makni F, Marrakchi S, Sellami H, Cheikhrouhou F, Bouassida S, Zahaf A, Ayadi A: Identification of Malassezia species from Tunisian

- patients with pityriasis versicolor and normal subjects. *Mycoses* 2005, 48:242- 45.
24. Zomorodian K, Mirhendi H, Tarazooie B, Zeraati H, Hallaji Z, Balighi K: Distribution of *Malassezia* species in patients with psoriasis and healthy individuals in Tehran, Iran. *Journal of cutaneous pathology* 2008, 35:1027- 31.
 25. Gupta AK, Foley KA: Antifungal Treatment for Pityriasis Versicolor. *Journal of Fungi* 2015, 1:13-29.
 26. Cafarchia C, Gasser RB, Figueredo LA, Latrofa MS, Otranto D: Advances in the identification of *Malassezia*. *Molecular and cellular probes* 2011, 25:17.
 27. Grover C, Vohra S: *Superficial Fungal Infections* edn 1st. india: Jaypee ,The health sciences publisher 2016.
 28. Wolstenholme A, Rogers A: Glutamate-gated chloride channels and the mode of action of the avermectin/milbemycin anthelmintics. *Parasitology* 2005, 131:S85- 95.
 29. Wang E-j, Lew K, Casciano CN, Clement RP, Johnson WW: Interaction of common azole antifungals with P glycoprotein. *Antimicrobial agents and chemotherapy* 2002, 46:160- 65.
 30. Lespine A, Ménez C, Bourguinat C, Prichard RK: Pglycoproteins and other multidrug resistance transporters in the pharmacology of anthelmintics: Prospects for reversing transport-dependent anthelmintic resistance. *International Journal for Parasitology: Drugs and Drug Resistance* 2012, 2:5875.
 31. Ci X, Li H, Yu Q, Zhang X, Yu L, Chen N, Song Y, Deng X: Avermectin exerts anti-inflammatory effect by downregulating the nuclear transcription factor kappa-B and mitogen-activated protein kinase activation pathway. *Fundamental & clinical pharmacology* 2009, 23:449- 55.
 32. Pitterna T, Cassayre J, Hüter OF, Jung PM, Maienfisch P, Kessabi FM, Quaranta L, Tobler H: New ventures in the chemistry of avermectins. *Bioorganic & medicinal chemistry* 2009, 17:4085-95.
 33. Pier AC, Ellis JA, Milis KW: Development of Immune Response to Experimental Bovine *Trichophyton verrucosum* Infection. *Veterinary Dermatology* 1992, 3:131- 38.
 34. Segura-Orsoni S, Diaz-Astruc F: Inverse emulsions comprising avermectins and cosmetic/dermatological applications thereof. Edited by: Google Patents; 2012.
 35. Okuda T, Fujiwara A: Calvatic acid production by the Lycoperdaceae, 2: Distribution among the Gasteromycetes. *Transactions of the Mycological Society of Japan (Japan)* 1982.
 36. Takaishi Y, Murakami Y, Uda M, Ohashi T, Hamamura N, Kidota M, Kadota S: Hydroxyphenylazoformamide derivatives from *Calvatia craniformis*. *Phytochemistry* 1997, 45:997- 01.
 37. Bouaziz M, Lassoued S, Bouallagui Z, Smaoui S, Gargoubi A, Dhouib A, Sayadi S: Synthesis and recovery of high bioactive phenolics from table-olive brine process wastewater. *Bioorganic & medicinal chemistry* 2008, 16:9238- 46.
 38. Fugmann B, Arnold S, Steglich W, Fleischhauer J, Reppes C, Koslowski A, Raabe G: Pigments from the Puffball *Calvatia rubro-flava*– Isolation, Structural Elucidation and Synthesis. *European journal of Organic chemistry* 2001, 2001:3097– 04.
 39. Lewis RE: Managing drug interactions in the patient with aspergillosis. *Medical Mycology* 2006, 44:349- 56.
 40. Chanwitheesuk A, Teerawutgulrag A, Kilburn JD, Rakariyatham N: Antimicrobial gallic acid from *Caesalpinia mimosoides* Lamk. *Food Chemistry* 2007, 100:1044- 48.
 41. Amer MA: Fluconazole in the treatment of tinea versicolor. *International journal of dermatology* 1997, 36:940- 42.
 42. Gopal S, Vasanthira K: Comparative Study Of Single High Dose Oral Fluconazole With Topical Clotrimazole In Patient With Localised Pityriasis Versicolor. *Journal of Drug Delivery and Therapeutics* 2015, 5:88-91.